Home-Based EEG Detection of REM Sleep Without Atonia as a Methodological Biomarker of Neurodegenerative Risk

Timothy Sheehan[1], Nurkurniati Tjiptarto[1], Dave Samuelson[1], Jayne Nerrie[1], Jay Pathmanathan[1], Jordan Dubow[2], Jacob Donoghue[1], Sagar Vaidya[3], Dave Matthews[1]

1 Beacon Biosignals, Boston, MA; 2 CLINTREX Research LLC, Sarasota, FL; 3 Cerevance Beta Inc.

Early manifestations of neurodegenerative disease are difficult to detect, yet sleep pathology is both common and clinically informative. We explore the use of an at-home EEG based sleep monitor to measure RSWA, a prodromal biomarker of REM behavior disorder (RBD). As an important prodromal indicator of disease conversion and severity, early indicators suggest this is a promising avenue for subsetting Parkinson's disease severity in existing clinical trials.

Introduction

Traditional RBD assessment relies on detecting REM sleep without atonia (RSWA)—a prodromal biomarker of RBD, Parkinson's disease, and other alpha-synucleinopathies — using polysomnography (PSG) with electromyography (EMG) leads. We propose that REM-related disturbances and broader sleep architecture abnormalities can instead be captured using EEG-based sleep monitors that clinical trial participants can operate autonomously at home over extended time periods. Moreover, automated detection of muscle artifacts during REM sleep from these EEG recordings may enable identification of RSWA. This work addresses the methodological challenge of quantifying RSWA from an at-home, wireless EEG wearable device without requiring additional sensors or in-lab visits. As RBD often goes undiagnosed for many years, early detection from easily accessible at-home measures is essential for improving patient outcomes as well as for better stratification of early- to late-stage PD patients in clinical trials.

In patients with RBD, conversion risk to neurodegenerative synucleinopathy (including PD) is 30% at 3 years and 66% at 7.5 years. Survival curve (adapted from Postuma et al., 2015) shown at right.

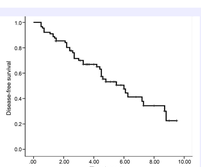

Conventionally, diagnosis of RSWA or RBD requires in-clinic PSG including chin, arm, and leg EMG. We observed that while in conventional PSG leg and chin EMG activity provided the most reliable signals of muscle activity during REM, concurrent muscle artifact on anterior EEG channels also revealed a strong signal.

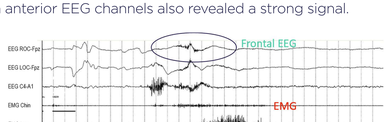

Example RSWA bout observed using conventional PSG including Chin and Leg EMG (adapted from McCarter et al. 2014). Just preceding loss of atonia in Leg and concurrent with Chin activity, high-frequency activity is seen in frontal electrodes.

Methods

We evaluated longitudinal sleep EEG data obtained from patients with Parkinson's disease who participated in the CVN424-203 Phase II study (n=30, 245 nights). This patient population has an elevated incidence of RSWA with 5 having a prior RBD diagnosis. REM sleep was automatically identified using an FDA-cleared sleep staging algorithm.

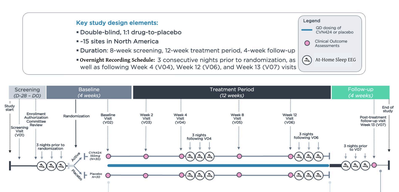

Trial schematic for Phase II study. Overnight at-home EEG was collected in sets of three consecutive nights at baseline, across two visits during the treatment period, and during follow up.

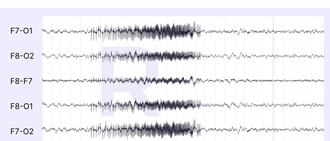

Example data recorded from the Waveband, an at-home EEG wearable device, from a participant with diagnosed RBD. During REM sleep (as classified by sleep staging algorithm), high amplitude high-frequency (30-50Hz) activity was observed across all channels with amplitude pattern suggesting an anterior origin.

Within REM, several features were examined to identify EMG artifact. We defined our RSWA index using the following procedure:

- F7-O1 and F8-O2 EEG was filtered to the 30-50 Hz band (4th order Butterworth)
- Variance was computed in 3 s windows
- For each contiguous REM period:
  - Baseline variance was defined as the 30th percentile
  - The mean % of 3 s periods that exceeded 4x baseline was counted
- The average % across all REM periods in a recording is the RSWA index

For analysis purposes, we considered all recordings with an RSWA index >2% RSWA positive. We observed that our performance was more reliable on nights with >1 hour of REM sleep and focused our analyses on this subset of recordings.

Results

The RSWA Index achieved modest single night predictive power (sensitivity=63%, specificity=74%, AUC=0.75). Examining cross-night reliability (ICC=0.60) we identified 12/24 RBD-negative participants as having perfect specificity (0% RSWA-positive) while 4/24 were identified as likely previously undiagnosed RSWA (>80% RSWA-positive).

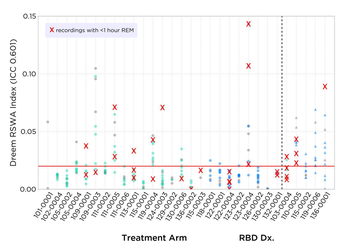

A post-hoc median split on baseline RSWA index revealed lower MDS-UPDRS scores in the RSWA-negative sub-group across Part I, II, and III (differences not significant). These findings demonstrate the feasibility of estimating RSWA from scalp-derived EMG activity and highlight its potential as a digital biomarker for early neurodegenerative change.

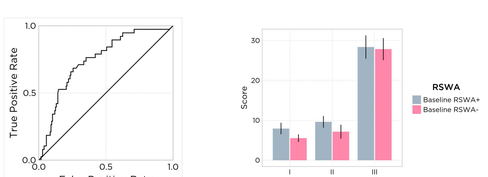

Left: ROC curve for recording-level RSWA classification, AUC=0.74. Right: Baseline MDS-UPDRS Scores split by RSWA+ status. Part I mean [se]; -2.4 [1.7], ns=16,13, p=.09; II: -2.5 [2.3] p=.14; III: -0.5 [4.0], p=.45)

Discussion

This methodological framework enables the use of advanced neurophysiological diagnostics that were previously impossible in decentralized trials. RSWA detection (along with evaluation of other sleep pathologies) offers insight into the dysfunction of deep sleep networks, providing a scalable means of identifying prodromal sleep-related dysfunction in a variety of neurodegenerative diseases. In this study we found:

- At-home EEG allows detection of muscle artifact indicative of RSWA. This RSWA index:
  - Was associated with prior RBD diagnosis as well as baseline disease severity
  - Was consistent and potentially prognostic, with 4/24 non RBD patients showing reliable RSWA.
- At-home sleep monitoring can be used for patient stratification and repeated measures can improve sensitivity and specificity.

Limitations:

- Home-based EEG sleep monitoring allows decentralized and longitudinal monitoring of RSWA, but scalp muscles may be less sensitive than muscles monitored on gold standard PSG (including chin and arm/leg channels). Future work must look at sensitivity and specificity differences between EEG methods and PSG with EMG leads.

Future Directions:

- RSWA detection from sleep EEG may be useful for initial diagnosis, clinical trial enrichment, or as a treatment response biomarker.
- Validation work leveraging simultaneous PSG could improve predictive power.

Conclusions

- **RSWA can be directly observed in high-frequency activity in both in-clinic PSG and ambulatory dry EEG.**
- **A derived RSWA index was predictive of RBD status and was reliable across repeated measures from an at-home, reduced-montage EEG device.**
- **Post hoc subgroup analysis by RSWA status revealed baseline differences in disease severity, which may inform response to treatment.**

References

1. Postuma, Ronald B., et al. "Parkinson Risk in Idiopathic REM Sleep Behavior Disorder: Preparing for Neuroprotective Trials." Neurology, vol. 84, no. 11, Mar. 2015, pp. 1104–13.
2. McCarter SJ, St Louis EK, Duwell EJ, Timm PC, Sandness DJ, Boeve BF, Silber MH. Diagnostic thresholds for quantitative REM sleep phasic burst duration, phasic and tonic muscle activity, and REM atonia index in REM sleep behavior disorder with and without comorbid obstructive sleep apnea. Sleep. 2014 Oct 1;37(10):1649-62. doi: 10.5665/sleep.4074

Disclosures: One or more authors report potential conflicts which are described in the program.

BEACONBIOSIGNALS